

# Androgen Receptor Expression in Adenoid Cystic Carcinoma of Breast: A Subset of Seven Cases

Seyran Yiğit<sup>1</sup> , Demet Etit<sup>1</sup> , Leyla Hayrullah<sup>1</sup> , Murat Kemal Atahan<sup>2</sup> 

<sup>1</sup>Department of Pathology, İzmir Katip Celebi University Atatürk Training and Research Hospital, İzmir, Turkey

<sup>2</sup>Department of General Surgery, İzmir Katip Celebi University Atatürk Training and Research Hospital, İzmir, Turkey

## ABSTRACT

**Objective:** Adenoid cystic carcinoma (ACC) of the breast is an uncommon salivary type of breast carcinoma. It is a triple negative breast carcinoma with a basal-like phenotype that behaves in an indolent manner. Herein, we aimed to document clinicopathologic findings and hormone receptor status of ACC in the breast diagnosed in our institution during an eleven-year period.

**Materials and Methods:** Medical data of cases diagnosed as adenoid cystic carcinoma in the breast between January 2006 and December 2016 were retrospectively reviewed from hospital data base. Paraffin blocks of seven cases were retrieved from the archive of Pathology Department and androgen receptor (AR) immunohistochemistry was applied to each case.

**Results:** All of the cases diagnosed as ACC were females with a mean age 56.2. Solid growth pattern was present in two cases. P63 was constantly expressed in the whole group, and at least one additional myoepithelial marker (calponin, caldesmon, etc.) was co-expressed in tumors. While weak estrogen receptor expression was detected only in one patient, AR was strikingly expressed in majority (85.7%) of the tumors.

**Conclusion:** To our knowledge, our series is the first to report such high levels of AR expression. This new finding, in turn, suggests considering hormonal therapy as an option in the management of ACC of the breast.

**Keywords:** Breast, adenoid cystic carcinoma, hormone therapy

**Cite this article as:** Yiğit S, Etit D, Hayrullah L, Atahan MK. Androgen Receptor Expression in Adenoid Cystic Carcinoma of Breast: A Subset of Seven Cases. Eur J Breast Health 2020; 16(1): 44-47.

## Introduction

Adenoid cystic carcinoma (ACC) of the breast is an uncommon salivary type of breast carcinoma which represents less than 0.1% of all breast malignancies. ACC of the breast is typically a triple negative carcinoma with rare axillary involvement, not in more than 5% of all cases (1). Similar to other breast malignancies, it is mostly seen in women in their 60s and 70s. The most common symptom is a palpable mass. Grossly, the tumor is a firm mass with a cystic cut surface, ranging in diameter from 1 to 3 cm. Histologically, it is composed of two types of cells: ductal epithelial cells lining true glandular luminal and basal/myoepithelial type cells surrounding eosinophilic cylinders composed of basement membrane like material (2). Similar to the ACC of the salivary gland, proportion of solid growth is the determinant of tumor grade: tumors with either cribriform or tubulo-trabecular pattern lacking solid areas are classified as grade I, tumors with ≤30% of solid growth as grade II, and tumors with >30% solid growth as grade III (3). It is generally negative for estrogen and progesterone receptors (ER and PR, respectively) as well as HER2/neu (c-erbB2). The c-Kit (CD117) positivity is a distinguishing characteristic for luminal epithelial cells. However, androgen receptor (AR) status of this rare tumor has not been well documented. Akin to its salivary gland counterparts, ACCs of the breast are characterized by the t(6;9) (q22-23; p23-24) chromosomal translocation, which generates fusion transcripts involving the oncogene MYB and the transcription factor gene NFIB (3, 4). Due to its rare incidence, the diagnosis and treatment protocol of this tumor is challenging (1-3, 5). Herein, we present a 10-year institutional feedback on ACC.

## Materials and Methods

The medical records of seven patients diagnosed with ACC of the breast between January 2006 and December 2016 were retrospectively retrieved from our local data base and reviewed in relation to the age at diagnosis, presenting complaints, operation modality, tumor size and loca-

tion, histopathologic features such as tumor grade and immunophenotype, axillary status, postoperative treatment choices [chemotherapy (CT) and radiation therapy (RT)], median follow-up period with outcome (i.e. overall survival and disease-free survival). AR immunohistochemically (IHC) was applied to one representative block in all cases. All IHC assays were performed by Leica BOND-III Fully Automated IHC&ISH Staining System (Leica Biosystems, Weltzar, Germany) The primary AR antibody (Clone EP 120, Cell Marque Sigma Aldrich Company, Darmstadt, Germany) was then applied at 1:150 dilution and incubated for 1 h.

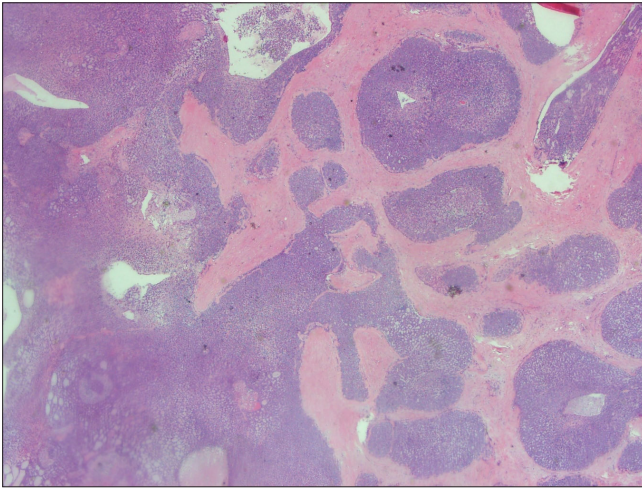
Ethics committee approval was received for this study from the ethics committee of İzmir Katip Celebi University School of Medicine (2019-GOKAE-1166). Written informed consent was obtained from patients who participated in this study.

## Results

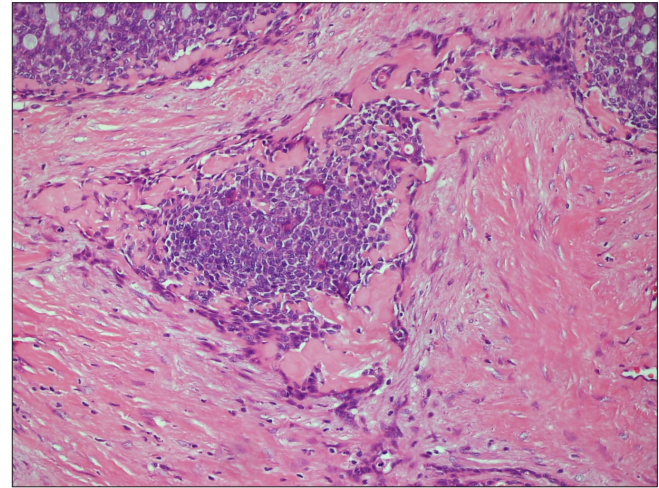
We found seven cases with ACC of the breast in an eleven year period. Out of seven 4 were consultation cases. The median age of the patients was 58, with a mean of 56.2. All patients presented with a palpable mass in the breast, except one with breast pain. None of the patients had a significant family history. Two of 7 patients (28.6%) developed recurrences following their primary treatment; recurrences occurred four years and sixteen years after the first diagnosis, in cases #1 and

#7, respectively. Left breast involvement was noted in six cases. Out of the seven patients, three underwent modified radical mastectomy (MRM), two breast-conserving surgery (BCS) with axillary dissection, one BCS with negative sentinel lymph node sampling and the last one, BCS only. Mean tumor size was 4.08 cm (Table 1). Majority of the tumors showed tubular-trabecular and cribriform growth patterns. In addition, glandular and pseudo-glandular structures were noted. Solid pattern of ACC was noted in two cases (cases #3 and #5) (Figure 1). The glands were formed by cells with round to oval nuclei and eosinophilic cytoplasm. Luminal PAS positive neutral mucin was present. Pseudo-cystic spaces were surrounded by cells with oval nuclei and scant cytoplasm. Eosinophilic basal membrane-like material was noted intermingling with glandular areas (Figure 2). Existence of solid component implies worse prognosis, however grading of ACC is still controversial (6). Only a single (14.3%) case of our series had a solid component (<30%, grade 2).

Six cases had neither ER nor PR hormone receptor expression, one showed (case #2) focal and weak ER positivity (5%). None of the cases showed HER2 positivity. Six tumors demonstrated cytoplasmic CD-117 expression (Figure 3). Of the applied myoepithelial markers such as calponin, caldesmon and smooth muscle actin, at least one was positive in each case. While CD10 was negative, p63 was steadily expressed in all cases. Positive expression in basal keratins such as keratin 5/6 or



**Figure 1.** Solid growth pattern in ACC



**Figure 2.** Basal membrane- like matrix surrounding tumoral nests

**Table 1.** Demographic features with treatment modalities and follow-up period of the cases

Case no	Age	Side/Operation	Axillary status	Treatment	Follow-up (mts)
1*†	58	L/MRM	RLH	CT+RT	96
2	58	L/BCS+AD	RLH	CT+HT	120
3‡	44	L/BCS+AD	RLH	CT+HT	86
4‡	57	L/BCS	Unknown	RT	84
5‡	50	R/BCS+SLN	RLH	CT	81
6	68	L/MRM	RLH	CT+RT	45
7**	59	L/MRM	RLH	CT+RT	204

BCS: Breast conserving surgery; AD: Axillary dissection; SLN: Sentinel lymph node; MRM: Modified radical mastectomy; mts: Months; CT: Chemotherapy; RT: Radiation therapy; HT: Hormone therapy \*Recurrence

†Exitus

‡Consultation case

Table 2. Immunohistochemical results of the tumors

Case no	Size (cm)	Grade	ER/PR	c-erbB2	AR	Ki67	BKs	CD117	P63	MEs
1	7.5	1	N/N	N	30% 1 (+)	%20	P	P	P	N
2	3	1	P/N	N	10% 3 (+)	15%	P	P	P	N
3	5	2	N/N	N	2% 1 (+)	%20	P	P	P	N
4	3	1	N/N	N	20% 2 (+)	10%	P	P	P	N
5	3	2	N/N	N	N	40%	P	P	P	N
6	3	1	N/N	N	1% 1 (+)	15%	P	P	P	P
7	?	1	N/N	N	10% 2 (+)	15%	P	P	P	P

ER: Estrogen receptor; PR: Progesterone receptor; N: Negative; P: Positive; AR: Androgen Receptor; BKs: Basal keratins; MEs: Calponin; caldesmon; smooth muscle actin

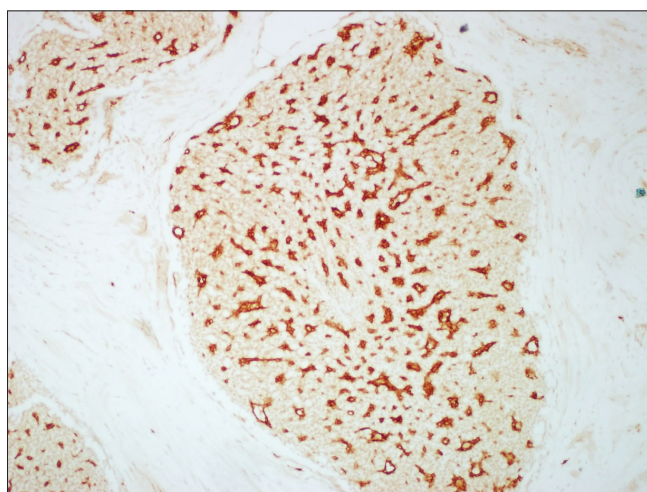


Figure 3. CD117 expression of the tumor cells

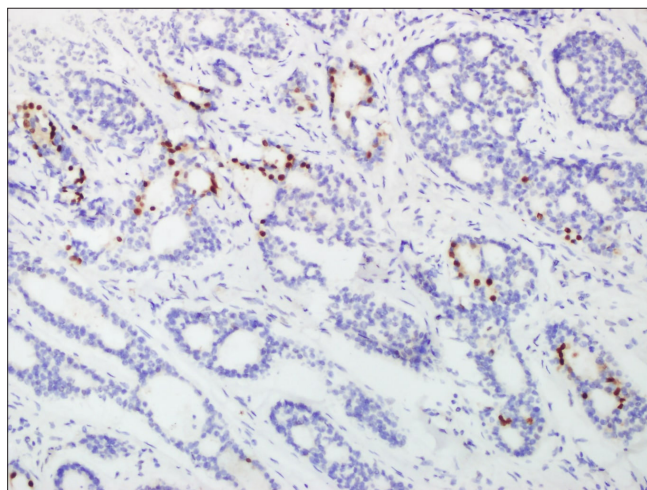


Figure 4. Nuclear AR positivity

keratin 14 was also conspicuous. Immunohistochemical test results have been shown in Table 2. AR positivity were noted in six cases (Figure 4). Percentage of AR IHC staining ranged from 1 to 30%, while staining intensity was ranked as weak (1+), moderate (2+) and strong (3+).

All cases of the series received either CT or RT, or both. Case #7 who had not undergone any post-operative treatment i.e. CT/RT follow-

ing the MRM, received both CT and RT after recurrence. Maximum follow-up period was 204 months with a mean of 102.2 months. All cases are alive, except for case #1 who died of an unknown cause eight years after the first diagnosis (Table 1).

## Discussion and Conclusion

Adenoid cystic carcinoma of the breast is mostly seen in adult women with a mean age of 59-63, as in our series (3, 7, 8).

Although, the majority of tumors were localized in the left breast in our series, there is no significant side predilection (2, 9). ACC of the breast is widely treated by BCS (3, 4, 7, 10). In the current study two cases were treated by BCS with axillary dissection, one case by BCS with sentinel lymph node sampling while one case was treated by BCS only. There were three axillary dissections performed in our series; one of them being sentinel lymph node sampling with a negative result. Since ACC is not a tumor with a tendency to metastasize to the lymph nodes, axillary dissection is not advised (7). The size of ACC varies from 0.5 to 12 cm with a mean of 1.8 to 3.5 cm in published series. Herein, the mean diameter was 3 cm in concordance with the literature (2, 3, 7, 8, 11-14). Histologically the tumor consists of epithelial and myoepithelial cells arranged in various architectural conformations such as classic tubular, trabecular, cribriform or solid. There were two cases containing solid components in our series. Recurrence was observed in case #1 only.

Based on immunohistochemical studies, ACCs are essentially hormone receptor (ER and PR) and HER2 negative tumors, which tend to express one or more basal/myoepithelial cell markers (CK5/6 and CK14) (7, 8, 11, 15). In our series, PR and c-erbB2 expressions were completely absent, while only a single weak ER positivity was observed, similar to the report of Viranic et al. (16). Applied basal markers such as keratin 5/6 and keratin 14 were strongly expressed in all tumors, and at least one myoepithelial differentiation marker expression was also present in our series. P63 nuclear positivity and CD117 expression was expectedly seen in all cases (2, 3, 6-8, 13, 15).

The differential diagnosis of the carcinoma includes cribriform ductal carcinoma in situ, invasive cribriform carcinoma, which are both the positive expression ER and PR while ACC is ER and PR negative. The basement membrane-like material found in the lumens of ACC does not exist in both in situ and invasive cribriform carcinoma. The invasive cribriform carcinoma lacks myoepithelial cells related to its



invasive characteristics. Collagenous spherulosis is a benign breast tumor and should be considered in the differential diagnosis. The collagenous spherulosis has acidophilic spherules rich in collagen, which have positive Periodic Acid-Schiff (PAS) staining and accompany usual type epithelial hyperplasia.

Androgen receptor status in ACC of the breast is restricted with case reports in the English literature (17, 18). In our series AR-IHC application resulted in 85.7% positivity (6 cases). The only AR negative case demonstrated a predominantly solid growth pattern (case #5). Solid component was more prominent in one of the cases with weak AR positivity (case #3). To our knowledge, the current study is the first report in a subset of a series with positive AR immunohistochemical results in contrary to the published papers. Since ACC of breast is usually considered in triple-negative category, hormonal therapy is not an indication in patient management. Based on our findings, we suggest AR positive patients to be considered for hormone therapy in the future. Undoubtedly, this idea needs to be confirmed by consecutive supportive studies. Unlike other triple-negative breast cancers that are associated with poor prognosis, ACC has an overall excellent prognosis. This rather intriguing situation might be explained by the presence of myoepithelial differentiation as in salivary glands (19).

Molecular studies have showed a translocation in t(6;9) involving oncogene MYB and NFIB in ACC of breast similar to its counterpart in the salivary glands. MYB-NFIB fusion may be considered for new therapeutic strategies. However, relevant molecular studies could not be performed in the current series due to institutional limitations.

In conclusion, ACC is an uncommon salivary type tumor of the breast. It is mostly negative for steroid hormones i.e. ER, PR and c-erbB2 however in the current study 85.7% of the tumors showed AR positivity. Patients with ACC in breast may also benefit from targeted hormone therapy. Moreover, CD117 positivity should be regarded not only for diagnostic purposes, but also for targeted therapy modalities of ACC.

**Ethics Committee Approval:** Ethics committee approval was received for this study from the ethics committee of İzmir Katip Celebi University School of Medicine (2019-GOKAE-1166).

**Informed Consent:** Written informed consent was obtained from patients who participated in this study.

**Peer-review:** Externally peer-reviewed.

**Author Contributions:** Concept - S.Y., D.E., L.H., K.A.; Design - S.Y., D.E.; Supervision - S.Y., D.E.; Resources - S.Y., D.E.; Materials - S.Y., D.E., L.H., K.A.; Data Collection and/or Processing - S.Y., D.E., L.H., K.A.; Analysis and/or Interpretation - S.Y., D.E., L.H., K.A.; Literature Search - S.Y., D.E., L.H., K.A.; Writing Manuscript - S.Y., D.E., L.H., K.A.; ; Critical Review - S.Y., D.E., L.H., K.A.

**Conflict of Interest:** The authors have no conflicts of interest to declare.

**Financial Disclosure:** The authors declared that this study has received no financial support.

## References

- Lakhani SR, Ellis IO, Schnitt SJ, Tan PH, van de Vijver MJ. WHO classification of tumours of the breast. Lyon: IARC; 2012.
- Kleer CG, Oberman HA. Adenoid cystic carcinoma of the breast: value of histologic grading and proliferative activity. *Am J SurgPathol* 1998; 22: 569-575. (PMID: 9591727) [\[CrossRef\]](#)
- Miyai K, Schwartz MR, Divatia MK, Anton RC, Park YW, Ayala AG, Ro JY. Adenoid cystic carcinoma of breast: Recent advances. *World J Clin Cases* 2014; 2: 732-741. (PMID: 25516849) [\[CrossRef\]](#)
- Skálová A, Stenman G, Simpson RHW, Hellquist H, Slouka D, Svoboda T, Bishop JA, Hunt JL, Nibu KI, Rinaldo A, Vander Poorten V, Devaney KO, Steiner P, Ferlito A. The role of molecular testing in the differential diagnosis of salivary gland carcinomas. *Am J SurgPathol* 2018; 42: e11-e27. (PMID: 29076877) [\[CrossRef\]](#)
- Acar T, Atahan MK, Çelik SC, Yemez K, Ülker GB, Yiğit S, Tarcan E. Salivary gland like breast carcinoma/adenoid cystic carcinoma: case report. *J Breast Health* 2014; 10: 245-247. (PMID: 28331680) [\[CrossRef\]](#)
- Foschini MP, Morandi L, Ascoli S, Giove G, Corradini AG, Eusebi V. The morphological spectrum of salivary gland type tumours of the breast. *J Pathol* 2017; 49: 215-227. (PMID: 28043647) [\[CrossRef\]](#)
- Treil D, Radkani P, Rizer M, El Hussein S, Paramo JC, Mesko TW. Adenoid cystic carcinoma of the breast, 20 years of experience in a single center with review of literature. *Breast Cancer* 2018; 25: 28-33. (PMID: 28466440) [\[CrossRef\]](#)
- Kulkarni N, Pezzi CM, Greif JM, Suzanne Klimberg V, Bailey L, Korourian S, Zuraek M. Rare breast cancer: 933 adenoid cystic carcinomas from the national cancer data base. *Ann Surg Oncol* 2013; 20: 2236-2241. (PMID: 23456318) [\[CrossRef\]](#)
- Ghabach B, Anderson WF, Curtis RE, Huycke MM, Lavigne JA, Dore GM. Adenoid cystic carcinoma of the breast in the United States (1977 to 2006): a population-based cohort study. *Breast Cancer Res* 2010; 12: R54. (PMID: 20653964) [\[CrossRef\]](#)
- Kocaay AF, Celik SU, Hesimov I, Eker T, Percinel S, Demirel S. Adenoid cystic carcinoma of the breast: a clinical case report. *Med Arch* 2016; 70: 392-394. (PMID: 27994304) [\[CrossRef\]](#)
- Kim M, Lee DW, Im J, Suh KJ, Keam B, Moon HG, Im SA, Han W, Park IA, Noh DY. Adenoid cystic carcinoma of the breast: a case series of six patients and literature review. *Cancer Res Treat* 2014; 46: 93-97. (PMID: 24520228) [\[CrossRef\]](#)
- Sherwell-Cabello S, Maffuz-Aziz A, Ríos-Luna NP, Bautista-Piña V, Rodríguez-Cuevas S. Salivary gland-like breast carcinomas: An infrequent disease. *Pathol Res Pract* 2016; 212: 1034-1038. (PMID: 27667558) [\[CrossRef\]](#)
- Azoulay S, Laé M, Fréneaux P, Merle S, Al Ghuzlan A, Chnecker C, Rosty C, Klijanienko J, Sigal-Zafrani B, Salmon R, Fourquet A, Sastre-Garau X, Vincent-Salomon A. KIT is highly expressed in adenoid cystic carcinoma of the breast, a basal-like carcinoma associated with a favorable outcome. *Modern Pathol* 2005; 18: 1623-1631. (PMID: 16258515) [\[CrossRef\]](#)
- Arpino G, Clark GM, Mohsin S, Bardou VJ, Elledge RM. Adenoid cystic carcinoma of the breast molecular markers, treatment, and clinical outcome. *Cancer* 2002; 94: 2119-2127. (PMID: 12001107) [\[CrossRef\]](#)
- Poling JS, Yonescu R, Subhawong AP, Sharma R, Argani P, Ning Y, Cimino-Mathews A. MYB Labeling by immunohistochemistry is more sensitive and specific for breast adenoid cystic carcinoma than MYB labeling by FISH? *Am J Surg Pathol* 2017; 41: 973-979. (PMID: 28498281) [\[CrossRef\]](#)
- Vranic S, Gatalica Z, Deng H, Frkovic-Grazio S, Lee LM, Gurjeva O, Wang ZY. ER-α36, a novel isoform of ER-α66, is commonly over-expressed in apocrine and adenoid cystic carcinomas of the breast. *J Clin Pathol* 2011; 64: 54-57. (PMID: 21045236) [\[CrossRef\]](#)
- Kumar BR, Padmanabhan N, Bose G, Paneer V. A case report of adenoid cystic carcinoma of breast- so close yet so far from triple negative breast cancer. *J Clin Diagn Res* 2015; 9: XD01-XD03. (PMID: 26393191) [\[CrossRef\]](#)
- Senger JL, Kanthan R. Adenoid cystic carcinoma of the breast a focused review. *JSM Surg Oncol Res* 2016; 1: 1008.
- Foschini MP, Reis-Filho JS, Eusebi V, Lakhani SR. Salivary gland-like tumours of the breast: surgical and molecular pathology *J ClinPathol* 2003; 56: 497-506. (PMID: 12835294) [\[CrossRef\]](#)