

# Dermatofibrosarcoma of The Breast – Case Report and Review of Literature

Amr Muhammed , Esraa Elnakib , Mahmoud Nady 

Department of Clinical Oncology and Nuclear Medicine, Sohag University Hospital, Sohag, Egypt

## ABSTRACT

Dermatofibrosarcoma protuberans is a rare form of soft tissue sarcoma that tends to invade and recur locally. The most common site of this disease is head, neck and extremities; however, the involvement of the breast has been reported. We present a case with a dermatofibrosarcoma of the breast that is composed of low-grade spindle cells which are positive for CD43. She was treated by wide surgical excision followed by adjuvant external beam irradiation at a dose of 60 Gray. After a follow-up of 24 months, no local-regional or distant recurrence was detected.

**Keywords:** Dermatofibrosarcoma, DFSP, dermatofibrosarcoma protuberans, dermatofibrosarcoma of the breast, radiotherapy in dermatofibrosarcoma

**Cite this article as:** Muhammed A, Elnakib E, Nady M. Dermatofibrosarcoma of The Breast – Case Report and Review of Literature. Eur J Breast Health 2018; 14(4): 234-237.

## Introduction

Dermatofibrosarcoma protuberans (DFSP) is very rare low-grade neoplasm that arises from the dermal fibroblasts. DFSP has an incidence less than 1 per 100,000 people annually (1). Few authors succeeded to link this a translocation between chromosome 7 and 22 leading to up-regulation of derived growth factor subunit B (PDGFB) gene (2, 3). Although it is common to see local recurrence following excision, this tumor rarely metastasizes. Clinically, it appears as a subcutaneous nodule that grows slowly without any pain (2). Despite its indolent behavior with three years survival rate nearly 90%, DFSP usually resistant to chemotherapy and radiotherapy, thus, complete surgical resection is the gold standard aim of the treatment. The commonest site for DFSP are head, neck and extremities, however, few authors reported the affection of other sites such as the breast, other body parts. This publication discusses the management of a case of DFSP in the breast (2).

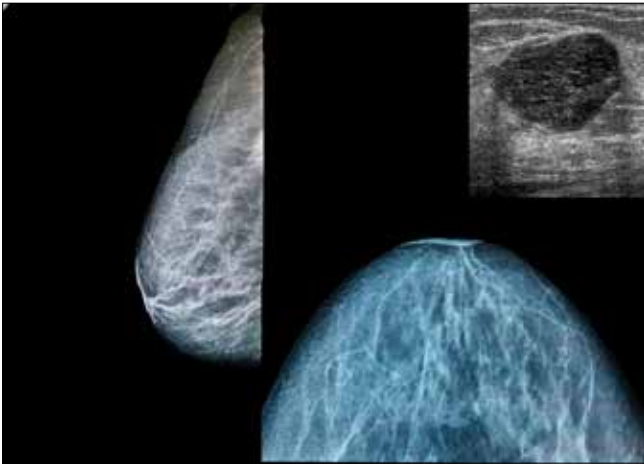
## Case Presentation

45 years old female presented to our department with a red-coloured subcutaneous right breast mass, 3 centimetres in maximal dimension and is located at the right lower quadrant of patient's breast. Her workup excluded any systemic metastasis (*Figure 1; Sono-mammographic imaging of the tumor*). At this stage, the provisional diagnosis was breast cancer with skin involvement. Biopsy from the nodule raised the suspicion of DFSP rather than breast cancer.

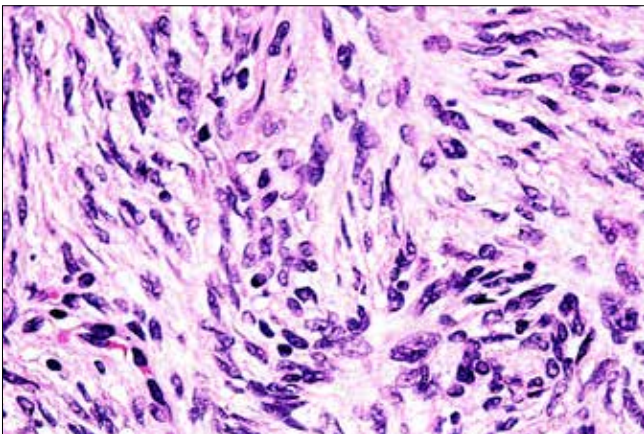
So, the patient was informed about the nature of her disease, the risk of its recurrence and the possible complications of the treatment in addition to that a written consent was taken from her before further steps in the treatment process.

She was subjected to wide resection with sentinel lymph node sampling which excluded any nodal involvement. Final pathological examination showed a tumour composed of malignant spindle cells (*figure 2 and 3; spindle shaped cells are arranged in storiform pattern*) that are CD 34 positive (*Figure 4; diffuse expression of CD34*) and CK, S100, ER, PR and CD 68 negative which suggest the diagnosis of low-grade dermatofibrosarcoma protuberans. The surgical resection margin was free of malignant cell involvement but less than 1.5 cm in width.

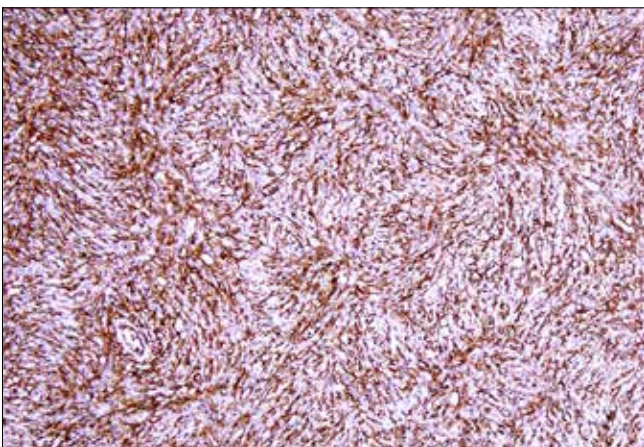
Due to high risk of local recurrence, she was planned to receive adjuvant external beam radiotherapy at a dose of 60 Gy using three-dimensional conformal radiotherapy, 3DCRT. She has CT simulation on breast board, supine position, in 5 mm thickness extending from the base of the skull to the level of the iliac crest. The organs at risk; both lungs, heart, right and left ventricles, liver, both kidneys and spinal cord were contoured.



**Figure 1.** a-c. Lateral (a), axial (b), sonographic (c) sonomammographic imaging of the tumor, the mass is only seen through ultrasound of the breast but not the mammography

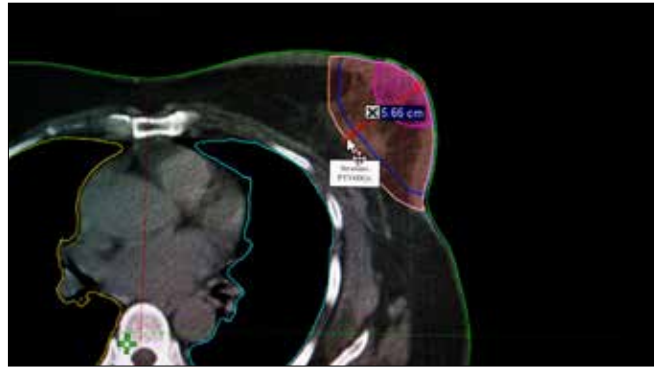


**Figure 2.** Low power H&E of the tumor, it show highly cellular tumors where cells are arranged in storiform pattern

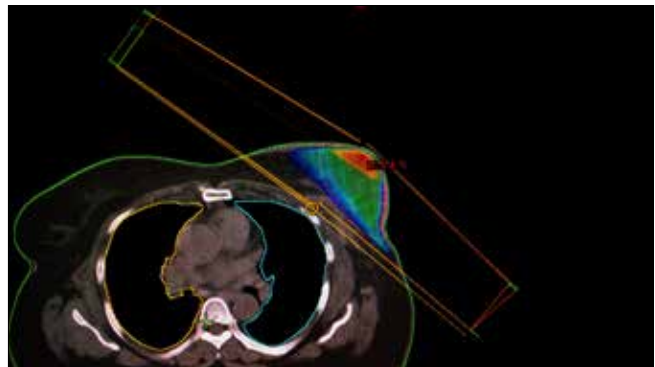


**Figure 3.** High power H&E of the DFS tumor. Tumor cells are spindle shaped admixed with histocytes. There are few mitosis

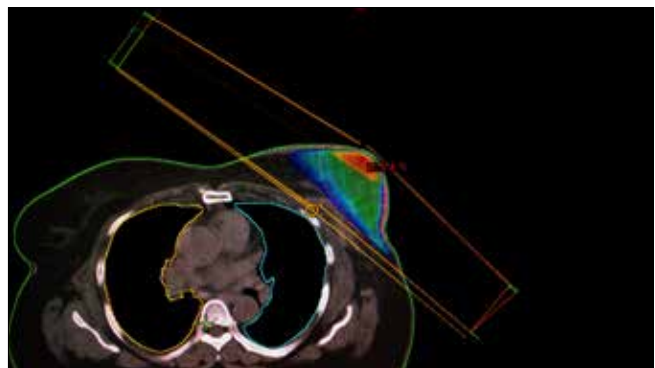
The tumour bed was identified, contoured and 3 centimetres margin is added to form the Clinical target volume receiving 60 Gy; CTV-60Gy (Figure 5; the generated CTV). An additional margin of 10 mm was added for the PTV60Gy. The physics plan was simple; just two opposing large fields and two small fields in fields, physical wedges



**Figure 4.** IHC staining of the tumor by CD34. The tumor cells show diffuse expression of CD34 marker



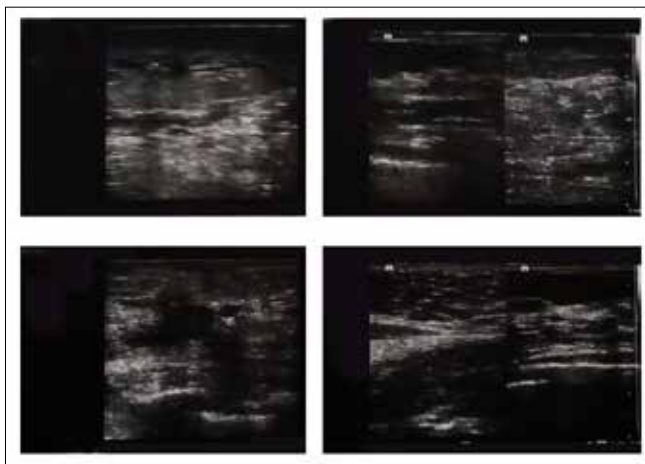
**Figure 5.** CT scanning was done for the patient where the operative bed was contoured then 3 cm margin is added to generate the CTV. Additional 10 mm is added to create the PTV to avoid mistreatment due to setup errors



**Figure 6.** Two lateral oblique wedged beams were used to provide at least 95% isodose coverage for the target. The maximum hot point identified is 105.4

were used to improve dose distribution (Figure 6; beam arrangements and PTV coverage by 95% of the dose). According to the DVH, 95% of the PTV is covered by 95% of the dose. The liver, lungs, right and left ventricles' mean doses are far below the recommended limits; V20 of right lung is limited below 10%, V25 of bilateral ventricle less than <5%.

After 24 months of follow up, no local regional recurrence was detected, however, she complained from dark skin discolouration and edema at the site of the radiotherapy (figure 7; edematous changes within the operative bed post radiation).



**Figure 7. a-d.** Soft tissue ultrasonographic imaging of the tumor bed show edematous changes, post radiation sequelae within the breast tissue without any suspicious recurrence

## Discussion and Conclusion

Although it is uncommon to face DFSP in current practice as its incidence is less than 1 in 100,000 individuals annually, it is quite rare to see them arising from the breast (1, 4). DFSP usually arise as a blue-reddish small subcutaneous mass that tends to grow slowly infiltrating the surrounding the subcutaneous tissue and fascia. This behaviour might be misleading when comes to the clinical practice since both advanced stage breast cancer and skin Squamous cell carcinoma are manifested with the similar clinical picture (1). DFSP rarely show systemic dissemination, even though, it might metastasize to lungs in less than 2% of the cases (5).

The pathological diagnosis of DFSP depends upon histopathological examination and immunohistochemistry (IHC) of the surgical specimen. This tumour usually characterized by being formed of spindle cells arranged in a storiform pattern with little nuclear pleomorphism and mitosis. DFSP are usually CD34 positive in 90% of the cases and negative to other markers such as S-100, actin and desmin (6).

Few publications have suggested a relationship between up-regulated PDGFB gene and occurrence of DFSP. This upregulation occurs secondary to the translocation between collagen type 1 gene located on chromosome 17 and platelet-derived growth factor B-chain located on chromosome 22 (3). Although, this translocation failed to predict the behaviour and mitotic potential of the disease, one publication suggested that the use of CD34 and D2-40 might do that role (6, 7).

Since DFSP is known to be chemotherapy and radiotherapy resistant, the main cornerstone of therapy is surgical resection with an adequate margin (8). DFSP tends to spread within the subcutaneous tissue and the underlying fascia and muscle, hence, it has high local recurrence rate, especially within the first three years post-resection (5). Despite that, it is still unknown the exact margin needed for the resection. It is widely accepted to excise the disease with margin not less than 2-3 centimetres across all tumour dimensions. In addition to that, adequate margin from the skin, subcutaneous tissue and fascia must be included in this resection (8, 9). The new novel techniques such as Mohs surgery are acceptable to reduce the recurrence rate only if it were used by experienced surgeons (10). Elective lymph node dissection failed to show any benefit in improving the

local recurrence rates (2). Several factors have been linked to the increased risk of local recurrences such as positivity of surgical margin and Ki67-index (11).

The use of adjuvant external beam irradiation has been linked to an improved local control following the excision, especially in those with adverse prognostic factors such as high Ki67 or positive margin (2, 12). Still, it is not well-known the recommended dose of radiotherapy in DFSP, however, many authors reported dose range between 55.8 – 66.0 Gy in standard fractionation, 1.8 – 2 Gy per fraction, in the adjuvant setting, however in the neoadjuvant setting the range was between 50 – 50.4 Gy (13, 14). Although these authors reported a local control rate post-radiotherapy up to 98% and 95% at 5 years and 10 years, these studies lacked the minimal requisites to accept them as strong medical evidence in favour of radiotherapy (14). They lacked the presence of comparative arms as well as appropriate randomization (15). In general, the adjuvant radiotherapy is an acceptable option for those with adverse factors to improve the local control.

Although several authors reported a case of DFSP in the breasts, this case remains to be unique since it represents a successful case that is not only treated by wide resection but also by adjuvant radiotherapy (5, 16-19). Despite the narrow resection margin with less than 1.5 cm, the use of adjuvant external beam irradiation, 60 Gray, succeeded to prevent local recurrence for the entire 24 months of the disease follow up.

Dermatofibrosarcoma is a rare neoplasm that originates from the fibroblast within the subcutaneous and fascial zones. Although it is quite common to see this neoplasm in the head, neck and extremities, it is uncommon to see it in the breast. Till now, no specific guideline recommendation for dealing with DFSP of the breast, however, current management is based on surgical excision with safety margin more than 2-3 cm beside adjuvant radiotherapy in case of narrow margin, recurrence or high mitotic index. This paper presents a case of DFS of the breast that had wide excision but with safety margin less than 1.5 cm followed by adjuvant external beam irradiation at a dose of 60 Gray to reduce the risk of recurrence. After 24 months of follow-up, the patient has no distant or loco-regional recurrence.

**Informed Consent:** Written informed consent was obtained from patient who participated in this study.

**Peer-review.** Externally peer-reviewed.

**Author Contributions:** Concept - A.M., M.N.; Design - E.E.; Supervision - A.M.; Resources - M.N.; Materials - A.M.; Data Collection and/or Processing - A.M.; Analysis and/or Interpretation - E.E.; Literature Search - E.E.; Writing Manuscript - A.M.; Critical Review A.M., M.N., E.E.; Other - M.N.

**Conflict of Interest:** The authors have no conflicts of interest to declare.

**Financial Disclosure:** The authors declared that this study has received no financial support.

## References

1. Chuang TY, Su WP, Muller SA. Incidence of cutaneous T cell lymphoma and other rare skin cancers in a defined population. *J Am Acad Dermatol* 1990; 23: 254-256. (PMID: 2170468) [CrossRef]
2. Llombart B, Serra-Guillen C, Monteagudo C, Lopez Guerrero JA, Sanmartin O. Dermatofibrosarcoma protuberans: a comprehensive review and update on diagnosis and management. *Semin Diagn Pathol* 2013; 30: 13-28. (PMID: 23327727) [CrossRef]

3. Nakanishi G, Lin SN, Asagoe K, Suzuki N, Matsuo A, Tanaka R, Makino E, Fujimoto W, Iwatsuki K. A novel fusion gene of collagen type I alpha 1 (exon 31) and platelet-derived growth factor B-chain (exon 2) in dermatofibrosarcoma protuberans. *Eur J Dermatol* 2007; 17: 217-219. (PMID: 17478383)
4. Pohlodek K, Meciarova I, Grossmann P, Kinkor Z. Dermatofibrosarcoma protuberans of the breast: A case report. *Oncol Lett* 2017; 14: 993-998. (PMID: 28693264) [[CrossRef](#)]
5. Dragoumis DM, Katsohi LA, Amlianitis IK, Tsiftoglou AP. Late local recurrence of dermatofibrosarcoma protuberans in the skin of female breast. *World J Surg Oncol* 2010; 8: 48. (PMID: 20525288) [[CrossRef](#)]
6. Sadullahoglu C, Dere Y, Atasever TR, Oztop MT, Karaaslan O. The Role of CD34 and D2-40 in the Differentiation of Dermatofibroma and Dermatofibrosarcoma Protuberans. *Turk Patoloji Derg* 2017; 1: 223-227. (PMID: 28832078) [[CrossRef](#)]
7. Saeki H, Tamada Y, Watanabe D, Akita Y, Matsumoto Y, Imai C, Kadono T, Maekawa T, Hattori N, Watanabe A, Torii H, Tamaki K. Analysis of gene mutations in four cases of dermatofibrosarcoma protuberans. *Clin Exp Dermatol* 2006; 31: 441-444. (PMID: 16681596) [[CrossRef](#)]
8. Loghdey MS, Varma S, Rajpara SM, Al-Rawi H, Perks G, Perkins W. Mohs micrographic surgery for dermatofibrosarcoma protuberans (DFSP): a single-centre series of 76 patients treated by frozen-section Mohs micrographic surgery with a review of the literature. *J Plast Reconstr Aesthet Surg* 2014; 67: 1315-1321. (PMID: 25012249) [[CrossRef](#)]
9. Arnaud EJ, Perrault M, Revol M, Servant JM, Banzet P. Surgical treatment of dermatofibrosarcoma protuberans. *Plast Reconstr Surg* 1997; 100: 884-895. (PMID: 9290656) [[CrossRef](#)]
10. Galimberti G, Montano AP, Kowalczyk A, Ferrario D, Galimberti R. Outcomes in 11 patients with dermatofibrosarcoma protuberans treated with Mohs micrographic surgery. *Int J Dermatol* 2012; 51: 89-93. (PMID: 22182384) [[CrossRef](#)]
11. Makkar M, Singh DP, Rana A, Madan M. Recurrent dermatofibrosarcoma protuberans: A continuing problem. *Indian Dermatol Online J* 2013; 4: 68-69. (PMID: 23437433) [[CrossRef](#)]
12. Bhambri S, Desai A, Del Rosso JQ, Mobini N. Dermatofibrosarcoma protuberans: a case report and review of the literature. *J Clin Aesthet Dermatol* 2008; 1: 34-36. (PMID: 21103308)
13. Williams N, Morris CG, Kirwan JM, Dagan R, Mendenhall WM. Radiotherapy for dermatofibrosarcoma protuberans. *Am J Clin Oncol* 2014; 37: 430-432. (PMID: 23388563) [[CrossRef](#)]
14. Castle KO, Guadagnolo BA, Tsai CJ, Feig BW, Zagars GK. Dermatofibrosarcoma protuberans: long-term outcomes of 53 patients treated with conservative surgery and radiation therapy. *Int J Radiat Oncol Biol Phys* 2013; 86: 585-590. (PMID: 23628134) [[CrossRef](#)]
15. Chen YT, Tu WT, Lee WR, Huang YC. The efficacy of adjuvant radiotherapy in dermatofibrosarcoma protuberans: a systemic review and meta-analysis. *J Eur Acad Dermatol Venereol* 2016; 30: 1107-1114. (PMID: 26879523) [[CrossRef](#)]
16. Jiang JQ, Huang Z, Wang LH, Shen SD, Lu H. Dermatofibrosarcoma protuberans of the breast: A case report. *Oncol Lett* 2014; 8: 1202-1204. (PMID: 25120687) [[CrossRef](#)]
17. Mirza TI, Akhtar K, Abbas HB, Sameena M, Tahir F, Khan S, et al. Dermatofibrosarcoma Protuberans Male Breast: A Case report. *Oman Med J* 2011; 26: e023. (PMID: 28845226) [[CrossRef](#)]
18. Shukla P, Gulwani HV. Dermatofibrosarcoma Protuberans of the Breast Skin Simulating Mammary Carcinoma. *Indian J Surg Oncol* 2017; 8: 198-202. (PMID: 28546720) [[CrossRef](#)]
19. Sin FN, Wong KW. Dermatofibrosarcoma protuberans of the breast: a case report. *Clin Imaging* 2011; 35: 398-400. (PMID: 21872132) [[CrossRef](#)]